



March 14, 2019

DIVISION MEMORANDUM  
No. 156, s. 2019

**REQUEST FOR VOLUNTARY FINANCIAL ASSISTANCE FOR  
MRS. RUBY D. ORBISO, TEACHER I OF BUANOY NATIONAL HIGH SCHOOL, BALAMBAN II DISTRICT**


To: Assistant Schools Division Superintendent  
CID and SGOD Chiefs  
CID and SGOD Personnel  
Public Schools District Supervisors  
Public Elementary and Secondary School Heads  
All Teaching and Non-Teaching Personnel

1. Attached is a letter from Mrs. Marivic M. Yballe, Principal II, Buanoy National High School, requesting for voluntary financial assistance for Mrs. Ruby D. Orbiso, Teacher I, Buanoy National High School, who is suffering from Breast Cancer Stage 3. She currently needs to undergo on 8 cycles of Chemotherapy and 60 days of radiation in order to control the disease.
2. Relative to the above mentioned circumstance, any voluntary contribution shall be remitted to Ms. Marites Peralta, Division Cashier who will turn over the money to her family through the school principal.
3. Immediate dissemination of this Memorandum is desired.

  
**RHEA MAR A. ANGTUD, Ed. D. CESO VI**  
Schools Division Superintendent



Republic of the Philippines  
Department of Education  
Region VII, Central Visayas  
DIVISION OF CEBU PROVINCE  
BALAMBAN DISTRICT II  
BUANOY NATIONAL HIGH SCHOOL  
Buanoy, Balamban, Cebu



March 12, 2019

DR. RHEA MAR A. ANGTUD, CESO VI  
Schools Division Superintendent  
Division of Cebu Province  
IPHO Bldg., Sudlon, Lahug  
Cebu City

Through:

Mr. Cristopher C. Piodos  
PSDS-Balamban II

Maam:

Greetings from Buanoy NHS!

This is in reference to the letter of Mrs. Ruby Orbiso, Teacher I of Buanoy National High School, Buanoy, Balamban, Cebu, requesting for financial assistance.

She has been diagnosed with INVASIVE DUCTAL CARCINOMA STAGE III C [INFLAMMATORY BREAST CANCER: LEFT BREAST MASS] last October 2018. She had undergone MODIFIED RADICAL MASTECTOMY last November 7, 2018 and was advised to undergo eight [8] cycles of Chemotherapy and proceed to a sixty [60] days of Radiation.

She was done with the fourth Chemotherapy cycle already and was scheduled for the fifth on March 14, 2019, however; due to financial constraints she had fears to be indefinitely rescheduled if she could not come up with the amount needed for the expenses of her succeeding Chemotherapies and Radiation.

It is on this premise that the undersigned through your good office knock at your benevolent hearts to please help Mrs. Ruby Orbiso of her financial needs.

It is earnestly hoped and prayed that this request be granted your most kind attention and approval.

Thank you very much and God bless!

Very respectfully yours,

MARIVIC M. YBALLE  
Principal II

EDWIN L. MARIBAO  
Asst. School Principal II-SHS

Noted:

CRISTOPHER C. PIODOS  
PSDS-Balamban II

March 12, 2109

Marivic M. Yballe  
Principal II  
Buanoy National High School

Madam:

Greetings of Peace and Love!

It is with a humble heart that I come to you to help me if I could possibly ask for financial assistance from the Department of Education, Division of Cebu Province for my Chemotherapy Cycles and Radiation.

I have been diagnosed with INVASIVE DUCTAL CARCINOMA STAGE III C (INFLAMMATORY BREAST CANCER; LEFT BREAST MASS) last October 2018 after experiencing complaints on my left breast mass. I had a surgery (MODIFIED RADICAL MASTECTOMY; left) last November 7, 2018 and was advised to undergo the eight (8) cycles of Chemotherapy and proceed to a sixty (60) days of Radiation.

As of this date, I am done with the 4<sup>th</sup> Chemotherapy cycles and I am scheduled for the 5<sup>th</sup> on March 14, 2019. I have also sought the help of other government agencies for my medicines and they have put me on a hold-on capacity due to the volume of requests they received.

I hope that with your help, this request would merit a positive response Madam.

Very truly yours,

  
Ruby Diaz Orbiso



**PERPETUAL SUCCOUR HOSPITAL OF CEBU, INC.**

P.O. Box 790, Cebu Central Post Office  
Cebu City  
6000 Cebu  
Philippines

# Medical Certificate

**TO WHOM IT MAY CONCERN:**

This is to certify that RUBY DIAZ ORBISO had  
been under treatment/confined at **Perpetual Succour Hospital of Cebu** from  
November 06, 2018 to November 10, 2018 for the following:

**DIAGNOSIS:**

INFLAMMATORY BREAST CANCER (INVASIVE DUCTAL  
CANCER) LEFT STAGE 3B (T4D,N2,MX)  
S/P CORE NEEDLE BIOPSY

**OPERATION:**

MODIFIED RADICAL MASTECTOMY, LEFT

**REMARKS:**

Issued this 10th day of November 2018 at Cebu City, Philippines for whatever legal purpose this  
will serve him/her best.

JONATHAN PLAZA, MD / Dr. Go! Carlos Antonio  
*Attending Physician*

PTR No.: \_\_\_\_\_  
Lic. No.: \_\_\_\_\_

0/34/20

CERTIFIED MACHINE COPY  
FROM THE ORIGINAL

MARTIN M. YBALLE  
PRINCIPAL



# PERPETUAL SUCCOUR

## HOSPITAL

Compassionate and World Class:  
The Sisters of St. Paul of Chartres Difference

### PATIENT DETAILS

NAME: ORBISO, RUBY DIAZ  
BIRTHDATE: December 04, 1980 AGE: 37 SEX: F  
BIRTHPLACE: CEBU CITY, CEBU  
ADDRESS: , BUANOY, BALAMBAN, CEBU  
PHONE NO.: 09229797916

### DISCHARGE SUMMARY / CLINICAL ABSTRACT

File copy in medical record

CASE NO.: 500815  
CIVIL STATUS: MARRIED  
CITIZENSHIP: FILIPINO

### ATTENDING PHYSICIAN

Name: PLAZA, JONATHAN HAVANA  
Address: SPC-MSR RM 407  
Schedule: 3-7 M-F, 10-12 SAT  
Phone: 412-2516

### ADMISSION DETAILS

Date Admitted: November 06, 2018  
Time: 8:37 am Room No.: SM-04

### DISCHARGE DETAILS

Date discharged: \_\_\_\_\_  
Time: \_\_\_\_\_

### DISCHARGE DIAGNOSIS:

Inflammatory breast cancer (invasive ductal carcinoma) left Stage II B (cT4bN2Mx) STP core needle biopsy  
STP Medically Radical Mastectomy left

### REVIEW OF CASE (Summary of presentation and progress in hospital):

4 months prior, noticed lump in areola noted, but intermittent growing pain PS 5-6/10, on mammography, excised by palpation, missed electrodiaagnosis - little pain on area of palpation, increased spontaneously, patient then sought consult with private MD, MRI was advised & mammal was made with suggestive of malignancy, enlarged left axillary tail & left axillary region lymph nodes, likely metastatic (core biopsy also done, results showed invasive ductal carcinoma, nuclear grade 2, thus advised for surgical).

P.E.: ABE, left breast (+) redness, (+) thickening of skin, nipple pointed outward, no discharge noted  
no retraction or dimpling.

Palpation (+) tenderness on all areas, hard irregular, poorly circumscribed nodules fixed in the skin.

EDICATION: Levofloxacin 500mg BID  
Ceftriaxone


ALLERGIES: Food peanut, seafood Drugs none Others skin asthma

### FUNCTIONAL STATUS:

Eyesight  No problem  Glasses  Blurred  Blind  
Hearing  No problem  Limited  Hearing Aid  
Speech  Clear  Slurred  Aphasic  
Continence  No problem  Incontinent  Foley Catheter  Condom Catheter  
Needs Assistance in  Feeding  Hygiene  Dressing  Transfer  
Mobility  No problem  Ambulates w/ Assistance  Breakfast  Bedfast  
Others \_\_\_\_\_

### NUTRITIONAL STATUS:

Diet  Oral  Tube  
Nutritional Risk  None  Minimal  
OUTCOME  Recovered  Improved  
DISPOSITION  As Advised  Transferred

  
SIGNATURE: Anaiti  
NAME: ANAMARIE D. MAJIM  
POSITION: MEDICAL RECORD CLERK  
DATE: NOV 10 2018  
High  Transfer  Bedfast  Against Advise

Condition related to transfer or change of patient's condition during transfer (Please see attached sheet/s)  
Your patient has / has not been given a copy of this summary (If not, state reason):  
PHOTOCOPIED FROM THE ORIGINAL

Physician-in-charge: MARTIN M. YBALLE Signature: \_\_\_\_\_ Date: 11/9/18  
License No.: \_\_\_\_\_ PTR No.: \_\_\_\_\_

Gorordo Avenue, Lahug, Cebu City 6000 Philippines  
Trunkline: (+6332) 233-8620 \* PSH Care Mobile: (+63927) 650-4065 \* PSH Care E-mail:  
Website: www.nshcehu.com



**PERPETUAL SUCCOUR HOSPITAL of CEBU INC.**  
Gorordo Avenue, Cebu City  
Tel. No. 2338620

**IMMUNOHISTOCHEMISTRY REPORT**



<b>ORBISO, RUBY DIAZ</b>	<b>37</b>	<b>F</b>	<b>11-08-2018</b>	<b>IHC18-247</b>
Patient's name	Age	Sex	Date	Pathology No.
Room	: SM-04			
Physician	: Dr. Plaza / Dr. Syban			
Source of Specimen	: Left breast mass (PSH-S18-2940)			
Clinical Impression	: Inflammatory Breast Cancer (Invasive Ductal carcinoma)			
History	: 6 months PTA, patient noticed onset of mid-axillar, left axilla non-tender, mobile, soft, well-circumscribed and _ mass. 3 months PTA, there was increase in size. 1 month PTA, mass became fixed, firm, non-tender, but eventually became tender with extension to the left breast and also with irregular, erythematous patches and _ on the skin of L breast. (-) weight loss, dyspnea, cough and fever.			


**I. ESTROGEN RECEPTOR ASSAY**

Immunohistochemical staining of tumor sections for Estrogen Receptor Assay failed to show nuclear staining of tumor cells examined.

**II. PROGESTERONE RECEPTOR ASSAY**

Immunohistochemical staining of tumor sections for Progesterone Receptor Assay failed to show nuclear staining of tumor cells examined.

	PERPETUAL SUCCOUR HOSPITAL CEBU CITY MEDICAL RECORDS DEPT.
SIGNATURE: 	
NAME: <b>MARIA LOTA L. AGUIRRE</b>	MEDICAL RECORDS CLERK
POSITION:	
DATE: 01-09-2018	
Note: Appropriate positive controls were performed.	
<b>CERTIFIED TRUE COPY</b>	

  
MARJORIE LIBRE-CANG, M.D.  
LICENSE NO. 0070348  
PTR 8869760  
01-09-2018 CEBU CITY  
TIN 158-543-103



# PERPETUAL SUCCOUR HOSPITAL of CEBU INC.

Gorordo Avenue, Cebu City

Tel. No. 2338620

## IMMUNOHISTOCHEMISTRY REPORT

<b>ORBISO, RUBY DIAZ</b>	<b>37</b>	<b>F</b>	<b>11-08-2018</b>	<b>IHC18-247</b>
Patient's name	Age	Sex	Date	Pathology No.
Room	: SM-04			
Physician	: Dr. Plaza / Dr. Syban			
Source of Specimen	: Left breast mass (PSH-S18-2940)			
Clinical Impression	: Inflammatory Breast Cancer (Invasive Ductal carcinoma)			
History	: 6 months PTA, patient noticed onset of mid-axillar, left axilla non-tender, mobile, soft, well-circumscribed and _ mass. 3 months PTA, there was increase in size. 1 month PTA, mass became fixed, firm, non-tender, but eventually became tender with extension to the left breast and also with irregular, erythematous patches and _ on the skin of L breast. (-) weight loss, dyspnea, cough and fever.			


### HER 2 (C-erbB-2) RECEPTOR ASSAY REPORT\*

Score	Result	Interpretation (cytoplasmic membrane staining)
( ) 3+	POSITIVE	Strong, complete membrane staining in >10% of invasive tumor cells.
( ) 2+	Equivocal	Weak to moderate complete membrane staining in >10% tumor cells. FISH is recommended.
( ) 1+	NEGATIVE	Faint / barely perceptible membrane staining in >10% of invasive tumor cells. The cells are only stained in part of their membrane.
(X) 0-	NEGATIVE	No membrane staining or membrane staining in <10% of invasive tumor cells.

(Consensus evaluation with other associate pathologists.)


PERPETUAL SUCCOUR HOSPITAL  
CEBU CITY  
MEDICAL RECORDS DEPT.

1936

SIGNATURE: 

DATE: **DEC 10 2018**

**CERTIFIED TRUE COPY**

  
**MARJORIE LIBRE-CANG, M.D.**  
 LICENSE NO. 0070348  
 PTR 8869760  
 01-09-2018 CEBU CITY  
 TIN 158-543-103

Note: Appropriate positive controls were performed.

This case was seen by four (4) reviewing pathologists.

\*Recommended by the American Society of Clinical Oncologists (ASCO) and adapted by the Philippine Society of Pathology

Encoded by: mem

Released Date: 11 17 20



# PERPETUAL SUCCOUR HOSPITAL of CEBU INC.

Gorordo Avenue, Cebu City

Tel. No. 2338620

## SURGICAL PATHOLOGY LABORATORY

<b>ORBISO, RUBY DIAZ</b>	<b>37</b>	<b>F</b>	<b>11-07-2018</b>	<b>S18-2940</b>
Patient's name	Age	Sex	Date	Pathology No.

Room : SM-04

Physician : Dr. Plaza / Dr. Syban

Source of Specimen : Left breast mass

Clinical Impression : Inflammatory Breast Cancer (Invasive Ductal carcinoma)

History : 6 months PTA, patient noticed onset of mid-axillar, left axilla non-tender, mobile, soft, well-circumscribed and \_ mass. 3 months PTA, there was increase in size. 1 month PTA, mass became fixed, firm, non-tender, but eventually became tender with extension to the left breast and also with irregular, erythematous patches and \_ on the skin of L breast. (-) weight loss, dyspnea, cough and fever.

### GROSS:

The specimen labeled "left breast", consists of a breast with axillary fat measuring 240 x 215x 80 mm. The overlying skin measures 150 x 105 mm. The nipple is off-center, firm and fixed measuring 16 mm in greatest diameter. Serial section of the underlying breast tissue shows an ill-defines, irregular, hard, firm mass on the left inner quadrant measuring 75 x 60 x 35 mm. The mass is noted 15 mm from the nearest resection margin. The mass presents with a \_ firm and \_ surface. Several matted lymph nodes are harvested, largest of which measures 80 mm in greatest diameter. Representative sections are processed labeled:

A = nipple B1 = mass with inked deep resection margin

Gross Examination By: Dr. Alessandra Kamille P. Mallari, Pathology Resident

PERPETUAL SUCCOUR HOSPITAL  
CEBU CITY  
MEDICAL RECORDS DEPT.

1936

SIGNATURE: *[Signature]*  
NAME: MARIA CTAL AGWANTY  
RESIDENT  
MEDICAL RECORD CLERK

DATE: DEC 10 2018

CERTIFIED TRUE COPY

### MICROSCOPIC:

Microscopic examination of slide A shows sections of nipple with malignant tumor cells which form nests and trabeculae invading the dermis and its lymphatic vessels. The nests of tumor cells push the epidermis from below but do not infiltrate it. As with slides labeled B, the tumor cells are pleomorphic with round to ovoid hyperchromatic nuclei, some with prominent nucleoli while the rest have indistinct or small nucleoli and minima cytoplasm. These form nests, trabeculae and occasional tubules. Mitotic activity is slightly increased. The tumor cells are found very close to the base resection margin, less than one millimeter in distance. Some of these cells occur as tumor emboli within the lymphovascular space.

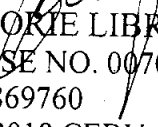
Slides labeled C show all thirty-six harvested axillary lymph nodes to be almost totally occupied by metastatic tumor infiltrates.




DIAGNOSIS:


LEFT BREAST

- MODIFIED RADICAL MASTECTOMY, LEFT
- INVASIVE DUCTAL CARCINOMA, NOTTINGHAM HISTOLOGIC GRADE II
- TUMOR SIZE : 7.5 cm
- INTRADUCTAL COMPONENT, SOLID AND COMEDO PATTERNS , <5%
- NEGATIVE FOR PAGET'S DISEASE
- POSITIVE OF LYMPHOVASCULAR SPACE INVOLVEMENT, DERMIS AND BASE
- TUMOR <1MM FROM BASE RESECTION MARGIN
- ALL THIRTY SIX AXILLARY LYMPH NODES POSITIVE FOR METASTATIC TUMOR WITH MATTED LYMPH NODES NOTED
- AJCC pT3N3Mx

  
MARJORIE LIBRE-CANG, M.D.  
LICENSE NO. 0070348  
PTR 8869760  
01-09-2018 CEBU CITY  
TIN 158-543-103

PERPETUAL SUCCOUR HOSPITAL  
CEBU CITY  
MEDICAL RECORDS DEPT.



SIGNATURE: 

NAME: **MARIA LOIAL AGWANTA**  
MEDICAL RECORD CLERK

POSITION: MEDICAL RECORD CLERK

DATE: **DEC 10 2018**

**CERTIFIED TRUE COPY**